

Acute “Olympic” Hepatitis: A Medical Experience from the Vancouver 2010 Games

Pamela Verma, BSc (Hons)^a, Mazhar Haque, MBBS, FRACP^b, Susan P.L. Tha, MD, PhD, FRCPC^c, James R. Gray, MD, FRCPC^{b,d}, Eric M. Yoshida, MD, MHSc, FRCPC^{b,d}

^aVancouver Fraser Medical Program 2012, UBC Faculty of Medicine, Vancouver, BC

^bDivision of Gastroenterology, University of British Columbia, Vancouver, BC

^cDepartment of Pathology and Laboratory Medicine, University of British Columbia, Vancouver, BC

^dVancouver 2010 Official On-Call Specialist Group, Gastroenterology, University of British Columbia, Vancouver, BC

ABSTRACT

A 50-year-old Chinese man, visiting for the Vancouver 2010 Winter Olympic Games Opening Ceremonies, was referred with acute-onset hepatitis. On presentation, he was found deeply jaundiced but without any clinical encephalopathy or stigmata of chronic liver disease. Initial laboratory investigations revealed acute liver failure that was complicated by renal impairment. His immediate prognosis was considered significant enough to result in referral to the liver transplant service. With increasing global travel, it is apparent that acute hepatitis E should be considered in the differential diagnosis of any patient with acute liver failure. Appropriate screening tests in this patient included hepatitis A, B and C viral serology and metabolic and autoimmune markers. The initial history suggested hepatotoxicity from traditional Chinese medicines; however, after a careful review via an interpreter, it was clear that the herbal medications were consumed after the patient became ill. Liver biopsy revealed features consistent with acute hepatitis E, which was confirmed by subsequent positive viral serology for the hepatitis E virus (HEV), particularly anti-HEV IgM. The patient’s liver function improved with conservative treatment, and he was able to return home.

KEYWORDS: *acute hepatitis, hepatitis E virus, hepatic failure, conservative treatment, olympic*

INTRODUCTION

As the influx of both international visitors and immigrants increases, the need for medical clinicians and trainees to be competent in considering and diagnosing “foreign” diseases is increasingly important. We provide here a case of hepatitis E virus (HEV) infection, which is typically considered only in endemic regions—particularly amongst pregnant women—and thus not considered in the differential diagnosis of acute hepatitis. Importantly, recent literature suggests that hepatitis E is becoming increasingly prevalent in the developed world, independent of immigration and travel history.¹

HEV is a single-stranded ribonucleic acid (RNA) virus that is transmitted primarily through the fecal-oral route. Another more recently identified transmission route is that of zoonotic foodborne transmission through swine, attributed as the source of autochthonous HEV infections reported in the developed world.² HEV classically is endemic in tropical and sub-tropical regions, including Asia and Africa, but there are increasing reports of its presentation among the general population in developed countries as well.² HEV can present in both epidemic and sporadic cases

within hyper-endemic regions. In both epidemic and sporadic cases, young adults are primarily affected, with no difference between sexes. Regions that report domestic cases of HEV are now considered “endemic” and include the United Kingdom, New Zealand, Taiwan, France, and Germany.³

The prevalence of HEV has traditionally been considered in two separate domains according to endemic and non-endemic. Endemic region outbreaks typically affect 1–15% of the population with the majority of victims being young adults (up to 30%) and the highest mortality rates among pregnant women (up to 19%).⁴ Non-endemic reports tend to be of isolated cases.

The diagnosis of HEV is made through the presence of Immunoglobulin M (IgM) antibodies against HEV or direct detection of the HEV viral particles in the serum or feces.

“

Hepatitis E is becoming increasingly prevalent in the developed world, independent of immigration and travel history.

Correspondence

Pamela Verma, pamverma@interchange.ubc.ca

Importantly, there is currently a great deal of variance in the sensitivity and specificity of these assays, making results less reliable than what is available for other strains of hepatitis viruses.⁵

CASE REPORT

A Chinese visitor in his mid-50s was referred for acute liver failure. He was unwell for six weeks prior to this presentation. His initial symptoms began within a few weeks of a recent inter-province travel in China. He became acutely unwell, suffering from lethargy, loss of appetite, nausea, abdominal bloating, discomfort, and occasional episodes of fever. His family members found him jaundiced one week after his initial symptoms. He had no previous diagnosis with any viral hepatitis. His reported alcohol history was very minimal. He consulted a Chinese medicine practitioner and started on herbal medications which he discontinued within two days due to lack of improvement. His symptoms persisted upon subsequent arrival in Vancouver, provoking him to visit a local primary care physician who then referred him for admission to hospital for liver transplant assessment.

His past medical history was significant for diabetes mellitus, hypertension, hypercholesterolemia, and obstructive sleep apnea. His regular medications included glyburide, pioglitazone, amlodipine, and atorvastatin. Apart from being from an endemic area, he had no other risk factors for horizontal transmission of viral hepatitis, such as intravenous drug use, tattoos, or a history of blood transfusion. His family history was insignificant for liver disease.

On presentation he was found febrile and deeply jaundiced but without stigmata of chronic liver disease, including portal hypertension and ascites. He did not develop encephalopathy at any stage. The remainder of his abdominal and physical exam was unremarkable. Ultrasonogram of his abdomen did not show any evidence of vascular or bile duct pathology. His initial calculated Child-Turcott-Pugh (CTP) score was 10 (Table 1),⁶ and his Model for End stage Liver Disease (MELD) score was 36 (Table 2)⁷ with a very abnormal cholestatic pattern of liver function test.

Table 1. Child-Turcotte-Pugh (CTP) Classification of the Severity of Liver Cirrhosis (Adapted from⁶).

Clinical and Biochemical Measurements	CTP points assigned for increasing abnormality		
	1	2	3
Encephalopathy (grade)	None	1–2	3–4
Ascites	None	Slight	Moderate
Bilirubin (µmol/L)	<34.2	34.2-51.3	>51.3
Albumin (g/L)	>35	28-35	<28
INR	<1.7	1.7-2.3	>2.3

CTP grade: A = 5–6 points (well-compensated disease) ; B = 7–9 points (significant functional compromise); and C = 10–15 points (decompensated disease) ; One- and two-year patient survival: grade A - 100 and 85 percent; grade B - 80 and 60 percent; and grade C - 45 and 35 percent.

He was reported to have an initial alanine transaminase (ALT) level of 1700 U/L (normal 25-80 U/L), which had decreased to 84 U/L upon transfer to our care. At this time his aspartate aminotransferase (AST) was 60 U/L (normal 10-30 U/L). However, his bilirubinemia remained alarmingly high: both total

Table 2. MELD (Model for End-stage Liver Disease)⁷.

$$(3.8[\text{Ln serum bilirubin (mg/dL)}] + 11.2[\text{Ln INR}] + 9.6[\text{Ln serum creatinine (mg/dL)}] + 6.4; \text{ where Ln is the natural logarithm}).$$

Most commonly-used prognostic model for estimating disease severity and survival in end stage liver disease. Originally developed to estimate procedure-related mortality in patients undergoing TIPS (transjugular intrahepatic portosystemic shunts). The MELD score is based on patients' laboratory values for serum bilirubin, serum creatinine, and international normalized ratio (INR) in a log transformed equation. High MELD scores are associated with a poor short-term prognosis. Three-month survival drops to less than 20 percent in patients with a MELD score of 40. An online MELD calculator that accepts SI units is accessible at <http://www.mdcalc.com/meld>.

bilirubin (reported 514 µmol/L, normal 0–18 µmol/L) and direct bilirubin (reported 412 µmol/L, normal 0–5 µmol/L). Hepatitis B virus surface antigen (HBs Ag) was negative with a hepatitis B surface antibodies (Anti-HBs) level of 1000 mIU/ml. However, his total Anti-Hepatitis B core (Anti-HBc) was positive. His Anti-HBc IgM was non-reactive, indicating a past infection. He tested negative for antibodies to the hepatitis C virus (Anti-HCV). All of his viral serologies for recent infections were negative, including those for cytomegalovirus, Epstein-Barr virus, herpes simplex virus, human immunodeficiency virus, and hepatitis A virus. His immunoglobulin levels were 18.1 g/L (normal 6.7–15.2 g/L), 6.52 g/L (normal 0.70–4.00 g/L), and 1.15 g/L (normal 0.40–2.30 g/L) for Immunoglobulin G (IgG), Immunoglobulin A (IgA), and IgM, respectively. He was negative for anti-parietal cell antibody, antimitochondrial antibody, antinuclear antibody, antinuclear cytoplasmic antibody (ANCA), anti-tissue transglutaminase, α1-antitrypsin, anti-smooth muscle antibody (1:40), and ceruloplasmin. Although he had episodes of fever, repeated blood cultures remained negative, and no obvious source of infection was ever isolated. His creatinine, elevated at 312 µmol/L (normal 60-115 µmol/L), was investigated for renal impairment and was thought to be due to pre-renal type etiology or possibly an early hepato-renal syndrome. However, this resolved promptly with intravenous fluid administration and resolution of the liver failure.

Routine investigations failed to provide a clear etiology for this patient's hepatitis, so a needle core biopsy of his liver was performed. Pathology showed an acute hepatitis with

Table 3. Patient's laboratory values on presentation.

Investigation	Patient's Value	Reference Range
ALT	84 U/L	25–80 U/L
AST	60 U/L	10–38 U/L
ALP(alkaline phosphatase)	166 U/L	90–210 U/L
GGT	407 U/L	15–80 U/L
Bilirubin Total	514 µmol/L	0–18 µmol/L
Bilirubin Direct	412 µmol/L	0–5 µmol/L
LDH(lactate dehydrogenase)	212 U/L	50–160 U/L
Sodium	134 mmol/L	135–145 mmol/L
Albumin	20 g/L	34–50 g/L
Creatinine	312 µmol/L	60–115 µmol/L
INR	1.3	1
PTT	34 secs	24–40secs
Platelets	199 giga/L	150–400 giga/L

unusual histopathologic features (Figure 1). Portal inflammation was present with a pattern of acute inflammation preferentially concentrated at interface, and chronic inflammation comprising lymphocytes and occasional plasma cells concentrated more centrally within the portal tracts. Damaged bile ducts were present, accompanied by considerable ductular proliferation. The lobular parenchyma showed occasional foci of acute inflammation, hepatocytolysis, and cholestasis. Mild steatosis and fibrosis were also present; these latter features are not characteristic of HEV infection and were attributed possibly to antecedent fatty liver disease secondary to the patient's diabetes mellitus.

His serology for hepatitis E IgM and IgG came back positive at a later date. After clinical review of the incubation time of acute HEV and the timeline of the patient's visit to Vancouver, it was apparent that the infection was acquired in Asia. Eventually, this patient's condition recovered with supportive management only, and he was able to return to China. The final clinical conclusion was that this patient's acute HEV was acquired in Asia, possibly from eating contaminated pork.

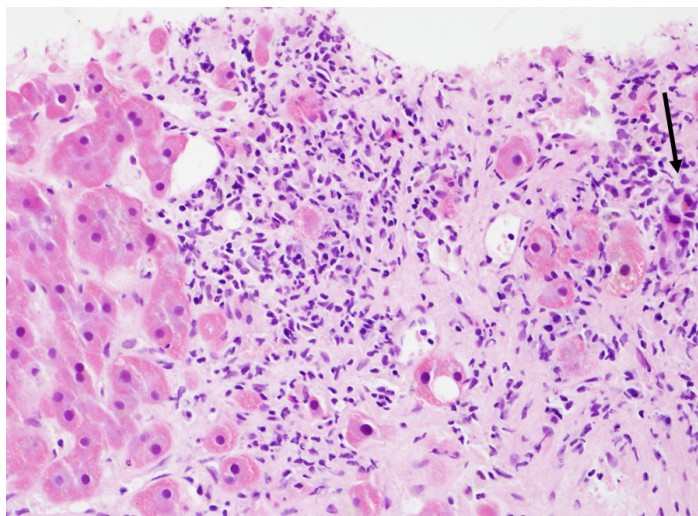


Figure 1. Liver core biopsy (hematoxylin and eosin stain; 200x magnification). Portal tract edge with predominantly neutrophilic infiltrate surrounding interface hepatocytes. Inflamed bile ductule is at extreme right (arrow).

DISCUSSION


We provide a poignant clinical case of acute-onset hepatitis caused by the hepatitis E strain. Although this is not a commonly seen causative factor, it is critical to consider in the differential diagnosis for any patient who presents with hepatitis. Consistent with previous reports, the HEV incubation period (2–9 weeks) is followed by the acute infection period at which point viral RNA is detected in blood and stool, and hepatocellular liver enzymes rise (peak approximately six weeks post exposure) with resolution at ten weeks exposure.¹ The most common prodromal symptoms are jaundice, followed by anorexia, lethargy, and abdominal pain.¹

The diagnosis of hepatitis E, compared to other etiologies, is critical as the treatment of acute hepatitis E is supportive since no specific anti-viral therapy exists. Provided the unclear etiology of this patient's hepatitis from routine labwork results, pathology was a critical component of the diagnosis. Two previous studies

“
...as the globalization of our population advances, so does the need for medical practitioners and trainees to think more globally in their diagnostic considerations.

characterised the histopathology of acute autochthonous HEV infections and reported a number of characteristic features also seen in the current case: intralobular neutrophilic inflammation and necrosis, neutrophilic interface inflammation with lymphocytic inflammation in the centre of portal tracts, and acute cholangitis and cholangiolitis.^{8,9}

An important advancement in the prevention of hepatitis E is the development of vaccinations. There are currently two in clinical trials: 1) a recombinant truncated capsid protein vaccine (Phase II) and 2) a recombinant structural protein (p239) vaccine (Phase III).^{2,10}

In conclusion, this report highlights the importance of considering HEV infection, regardless of exposure history, in the case of acute hepatitis. However, there is a broader lesson as well: as the globalization of our population advances, so does the need for medical practitioners and trainees to think more globally in their diagnostic considerations. The 2010 Winter Olympic Games brought an unprecedented degree of international media attention to Vancouver. Post-Olympics, it can be anticipated that Vancouver will be a destination for international visitors for years to come, and the British Columbian medical community will need to prepare for this. 

SOAP Note.

Subjective

A male, Chinese tourist, mid-50s, was referred for jaundice. He was unwell for six weeks prior to this presentation. He became acutely unwell, suffering from lethargy, loss of appetite, nausea, abdominal bloating, discomfort, and occasional episodes of fever. No previous diagnosis with any viral hepatitis nor significant alcohol or drug use. However, he reported using Chinese herbal medications.

Objective

He was found deeply jaundiced but without stigmata of chronic liver disease (ascites, portal hypertension, and encephalopathy). He had a transaminitis ALT 1700 U/L (normal 25-80 U/L). He tested negative for hepatitis A, B, and C. Liver biopsy revealed acute portal inflammation preferentially concentrated at the interface. His serology for hepatitis E IgM and IgG came back positive at a later date.

Assessment

Acute hepatitis E viral infection causing hepatic failure, likely contracted from contaminated meat products in Asia.

Plan

Conservative management with close supervision resulted in full recovery.

REFERENCES

1. Dalton HR, Bendall R, Ijaz S, Banks M. Hepatitis E: an emerging infection in developed countries. *Lancet Infect Dis.* 2008 Nov;8(11):698-709.

2. FitzSimons D, Hendrickx G, Vorsters A, Van Damme P. Hepatitis A and E: update on prevention and epidemiology. *Vaccine*. 2010 Jan 8;28(3):583-588.
3. Teo CG. Much meat, much malady: changing perceptions of the epidemiology of hepatitis E. *Clin Microbiol Infect*. 2010 Jan;16(1):24-32.
4. Aggarwal R, Naik S. Epidemiology of hepatitis E: current status. *J Gastroenterol Hepatol*. 2009 Sep;24(9):1484-1493.
5. Purcell RH, Emerson SU. Hepatitis E: an emerging awareness of an old disease. *J Hepatol*. 2008 Mar;48(3):494-503.
6. Pugh RN, Murray-Lyon IM, Dawson JL, Pietroni MC, Williams R. Transection of the oesophagus for bleeding oesophageal varices. *Br J Surg*. 1973 Aug;60(8):646-649.
7. Kamath PS, Wiesner RH, Malinchoc M, Kremers W, Therneau TM, Kosberg CL, *et al*. A model to predict survival in patients with end-stage liver disease. *Hepatology*. 2001 Feb;33(2):464-470.
8. Peron JM, Danjoux M, Kamar N, Missouri R, Poirson H, Vinel JP, *et al*. Liver histology in patients with sporadic acute hepatitis E: a study of 11 patients from South-West France. *Virchows Arch*. 2007 Apr;450(4):405-410.
9. Malcolm P, Dalton H, Hussaini HS, Mathew J. The histology of acute autochthonous hepatitis E virus infection. *Histopathology* 2007 Aug;51(2):190-194.
10. Zhu FC, Zhang J, Zhang XF, Zhou C, Wang ZZ, Huang SJ, *et al*. Efficacy and safety of a recombinant hepatitis E vaccine in healthy adults: a large-scale, randomised, double-blind placebo-controlled, phase 3 trial. *Lancet*. 2010 Sep 11;376(9744):895-902.

The Hidden Time Bomb Explodes: A Previously Asymptomatic and Undiagnosed Hepatocellular Carcinoma Presenting as a Tumour Rupture

Inna Sekirov, BSc^{a,c}, Carrie Yeung, BSc^{a,c}, Allison C. Harris, MD^b, Jennifer Montis, MD^b, Albert Chang, MD^b, Eric M. Yoshida, MD^b

^aVancouver Fraser Medical Program 2011, UBC Faculty of Medicine, Vancouver, BC

^bVancouver General Hospital, University of British Columbia, Vancouver BC

^cAuthors contributed equally to this work

ABSTRACT

Hepatocellular carcinoma is the third leading cause of cancer-related death world-wide. Infection with hepatitis B virus is the strongest known risk factor for the development of hepatocellular carcinoma, especially in male patients. Regular surveillance is crucial for early detection of hepatocellular carcinoma as, in the absence of consistent follow-up, patients often present with advanced disease and sometimes with tumor rupture. We present here a case report of a patient from a high risk demographic—an African male infected with hepatitis B virus—whose initial presentation of hepatocellular carcinoma was that of a tumor rupture. We highlight the non-specific nature of his presentation and the importance of high clinical suspicion for hepatocellular carcinoma in patients from high-risk groups. We highlight that in the absence of timely recognition of this malignancy, especially at its advanced stage, a patient's already scarce treatment options may become even more limited.

KEYWORDS: *hepatocellular carcinoma, hepatitis B virus, tumour rupture, transarterial embolization*

INTRODUCTION

Hepatocellular carcinoma (HCC) is the third leading cause of cancer-related mortality in the world,¹ with a specific geographic distribution and strong association with hepatitis B or C virus (HBV and HCV) carrier status.^{2,3} It is especially prevalent in Sub-Saharan Africa, with Gambia specifically having the incidence of 33.1 per 100,000 males per year and 12.6 per 100,000 females per year.^{4,5} The increased susceptibility of males

“ We highlight that in the absence of timely recognition of this malignancy, especially at its advanced stage, a patient's already scarce treatment options may become even more limited.

Correspondence

Inna Sekirov, innas@interchange.ubc.ca